CGuard's EPS position in expanding the endovascular route of carotid revascularosation: surgeon's viewpoint

W. Kuczmik

Ł. Szkółka

Klinika Chirurgii Ogólnej, Naczyń, Angiologii i Flebologii

GCM ŚUM

CAS EPS

- Carotid atherosclerosis is an important reason of ischemic stroke.
- Patients with neurological symptoms and stenosis over 50% / asymptoatic patients with 70% or higher stenosis are treated using CAS/CEA methode
- CAS established it's place, in the last two decades as a valid carotid revascularisation methode

CAS EPS

- atherosclerotic plaque protrusion, through the carotid stent struts is a leading mechanism of peri- and postoperative cerebral embolisation
- classic carotid stents structure is an important reason of struts protrusion
- EPD reduce the risk of cerebral embolisation

CAS EPS

- the ultra closed stent cell system may help, to further reduce risk of peri- and posoperative ischemic stroke events
- new stents assisted by EPD may also allow safe CAS treatment of high- risk carotid artery plaques
- these methodes open new perspectives for patients with high risk CEA

CAS EPS

- There are three kinds of mesh covered stents:

- a)RoadSaver/Casper (Terumo/Microvention)

- b) CGuard Embolic Prevention Stent (CGuard EPS, InspireMD)

- c) Gore hybrid stent (Gore)

CAS EPS

- CGuard Embolic Prevention Stent- used in presented cases
- nitinol, open cell stent
- outside of the frame is covered with PET single-fibre knitted MicroNET mesh
- mesh pore size 150–180 μm

CAS EPS



CAS EPS

- EPD- SpiderFX (Medtronic)



CAS EPS



Fot. dr J. Żmudzki

CAS EPS



Fot. dr J Żmudzki

CAS EPS

Case nr 1

- Male, 64 y.o.
- critical stenosis RICA, high-risk plaque
- neurological symptoms
- history of arterial hypertension

CAS EPS

Case 1

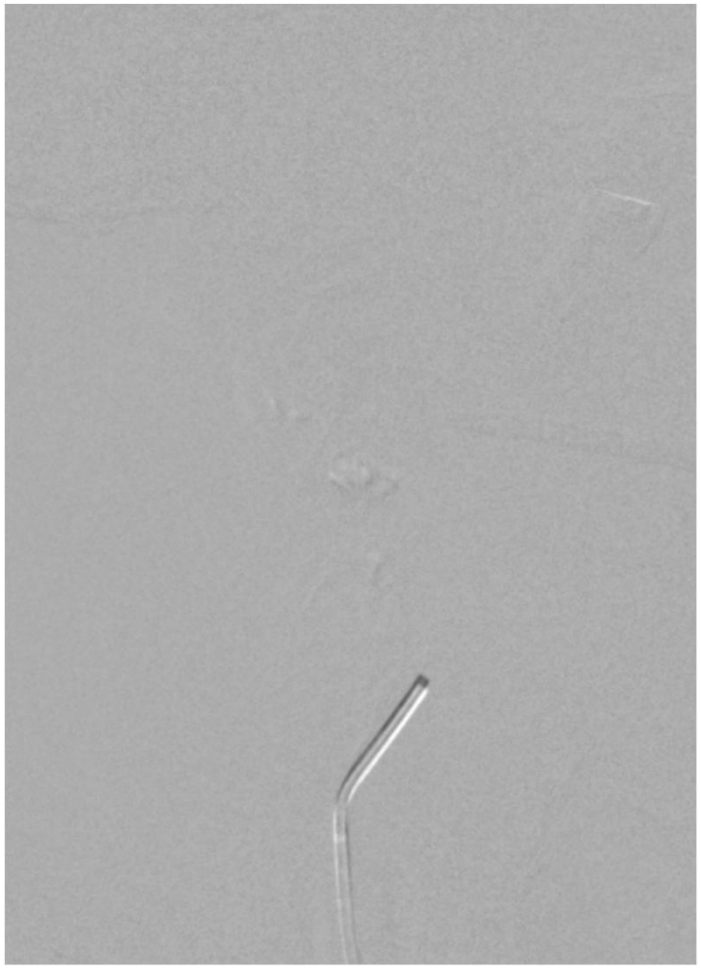

Case 1

CAS EPS

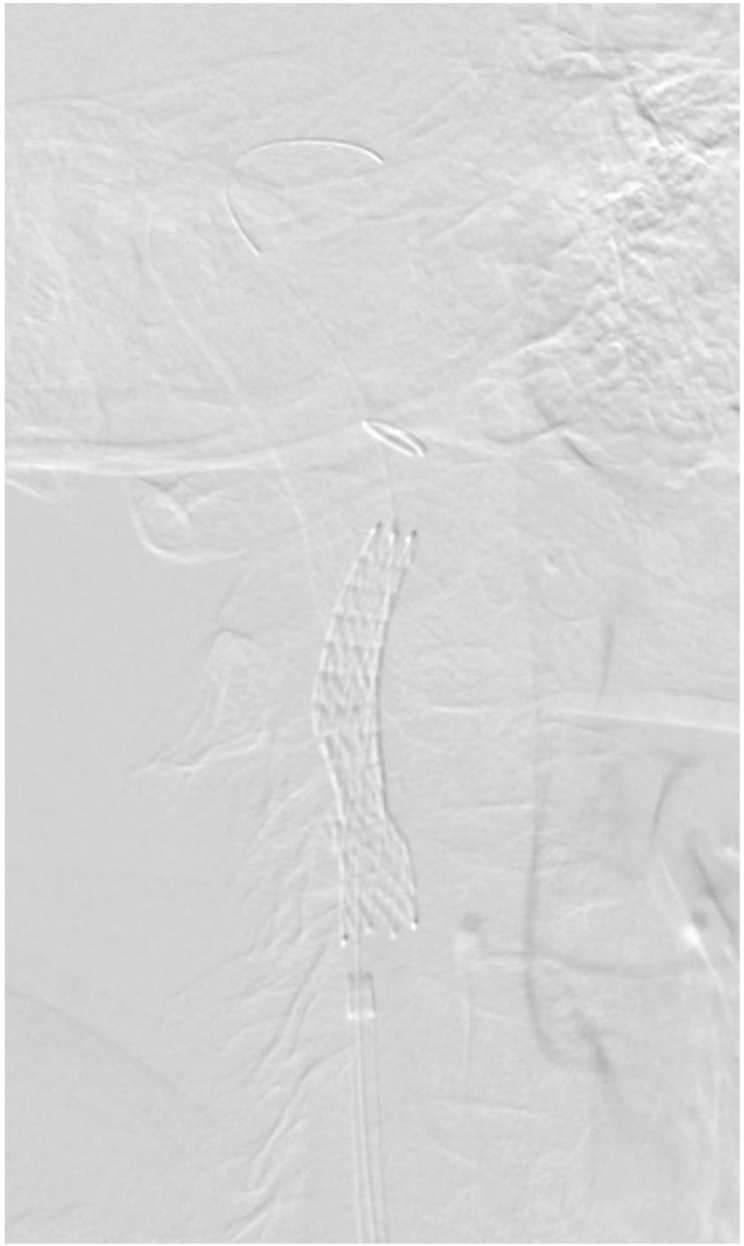

CAS EPS

Case nr 2

- Male, 74 y.o.
- critical stenosis LICA, high-risk plaque
- neurological symptoms
- history of arterial hypertension

CAS EPS

Case 2

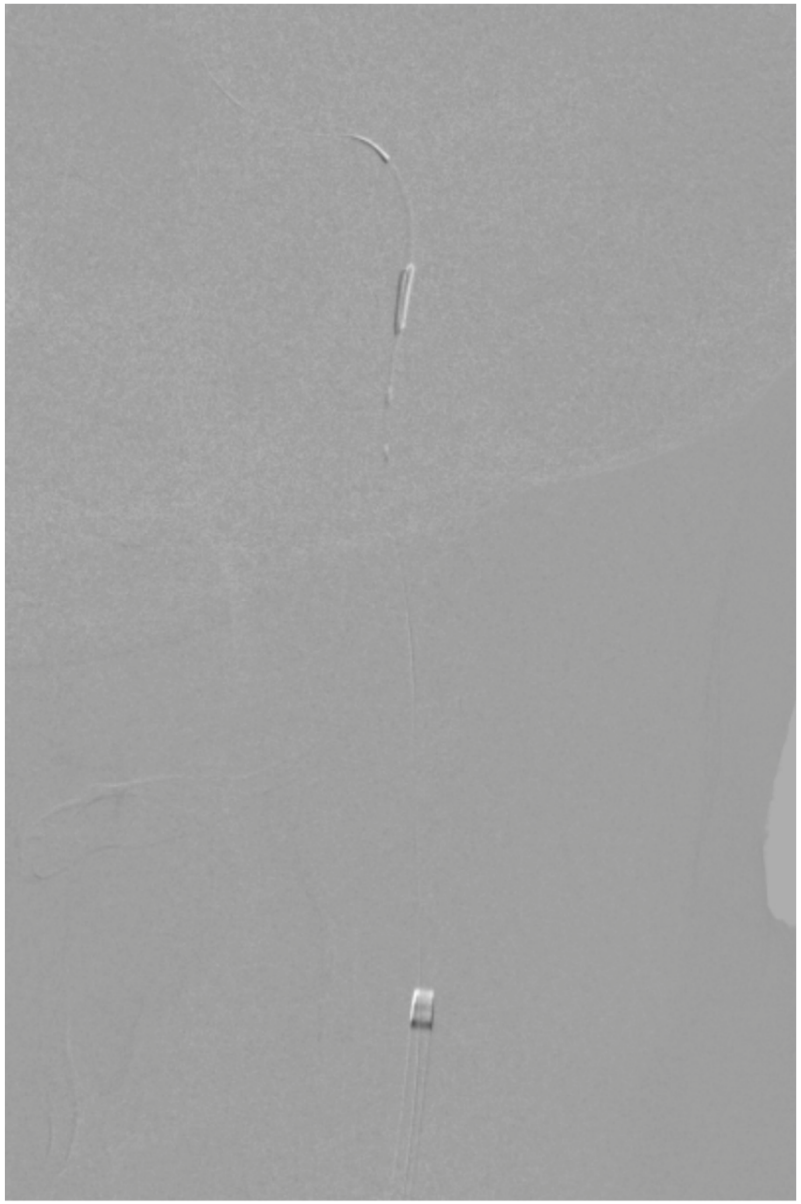

CAS EPS

Case 2

CAS EPS

Case nr 3

- Male, 69 y.o.
- 80% stenosis LICA, high-risk plaque
- neurological symptoms
- history of arterial hypertension, CMI

Case 3

CAS EPS

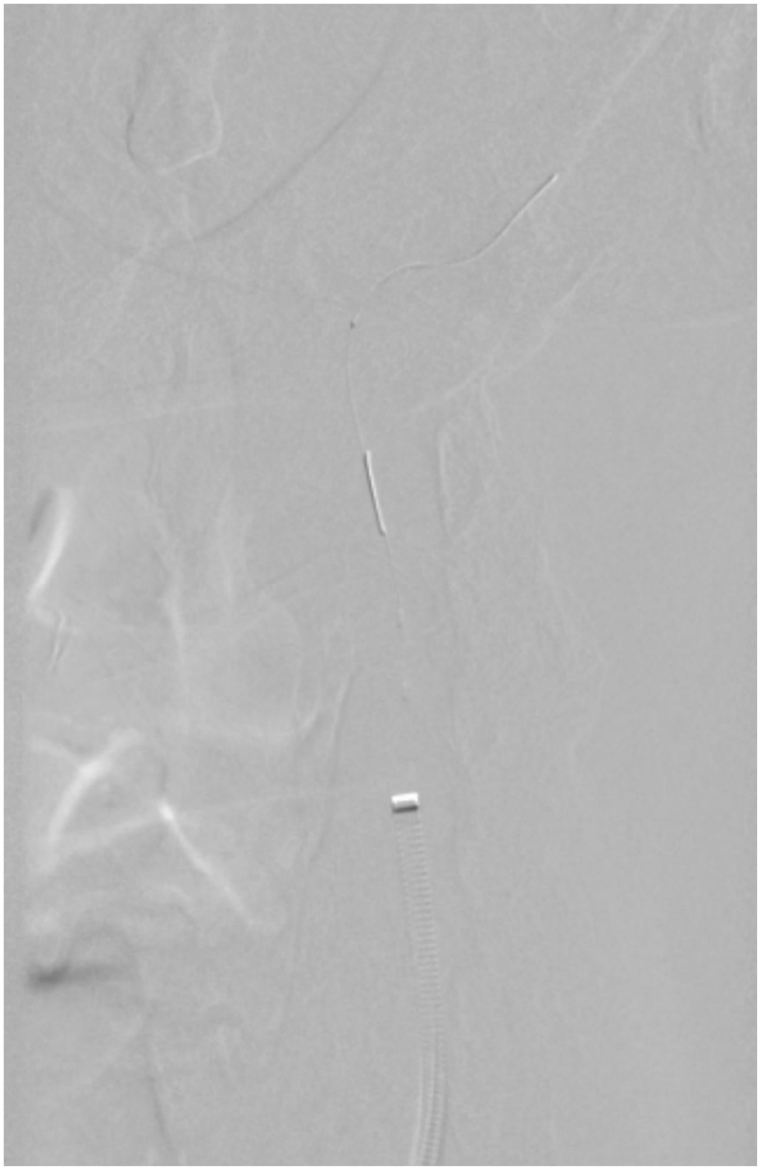

Case 3

CAS EPS

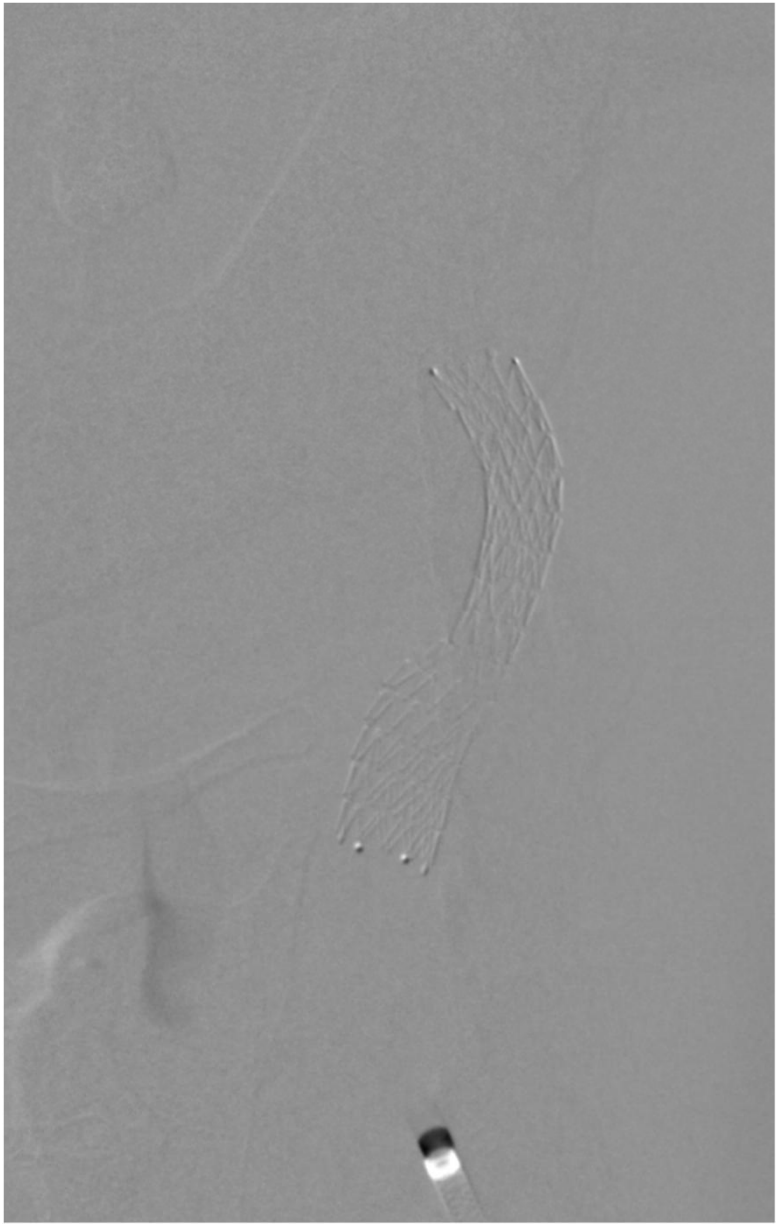

CAS EPS

Case nr 4

- Male, 73 y.o.
- Kinking and stenosis LICA, high-risk plaque
- neurological symptoms
- history of arterial hypertension

Case 4

CAS EPS

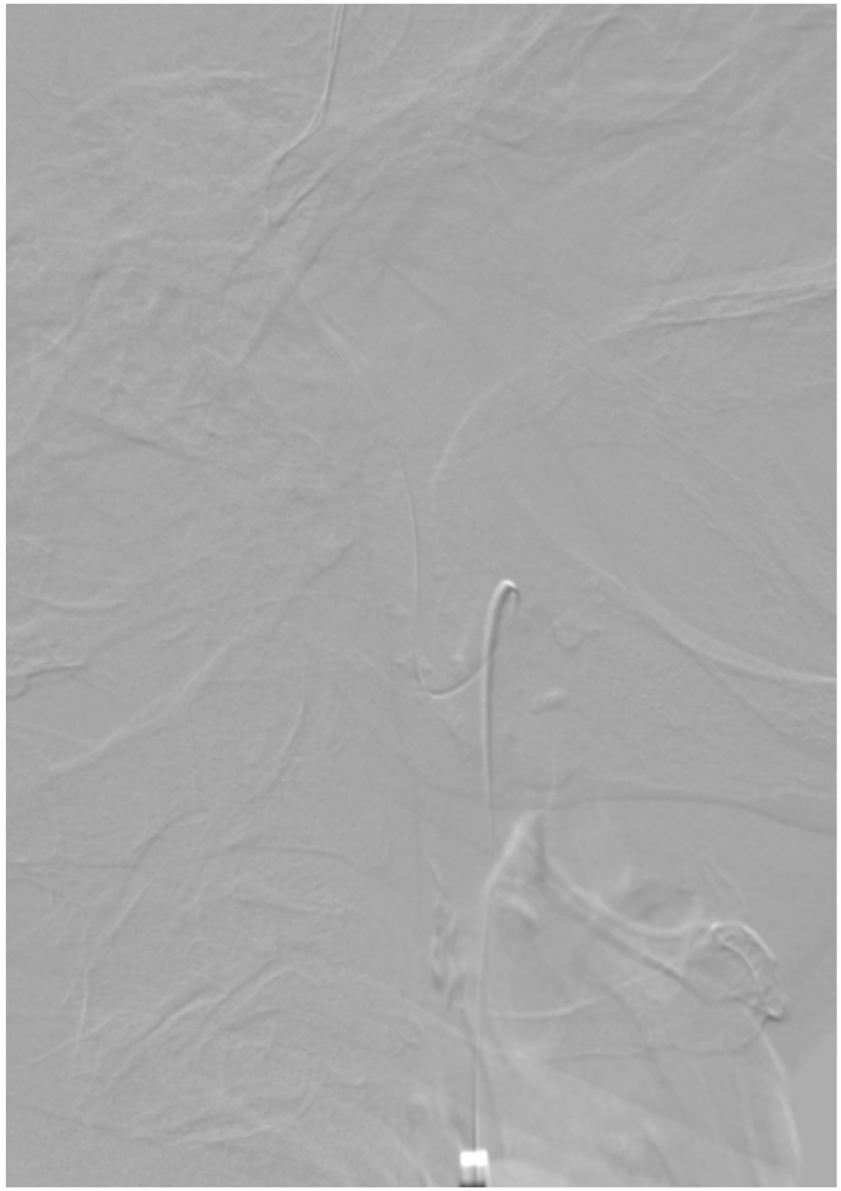

Case 4

CAS EPS

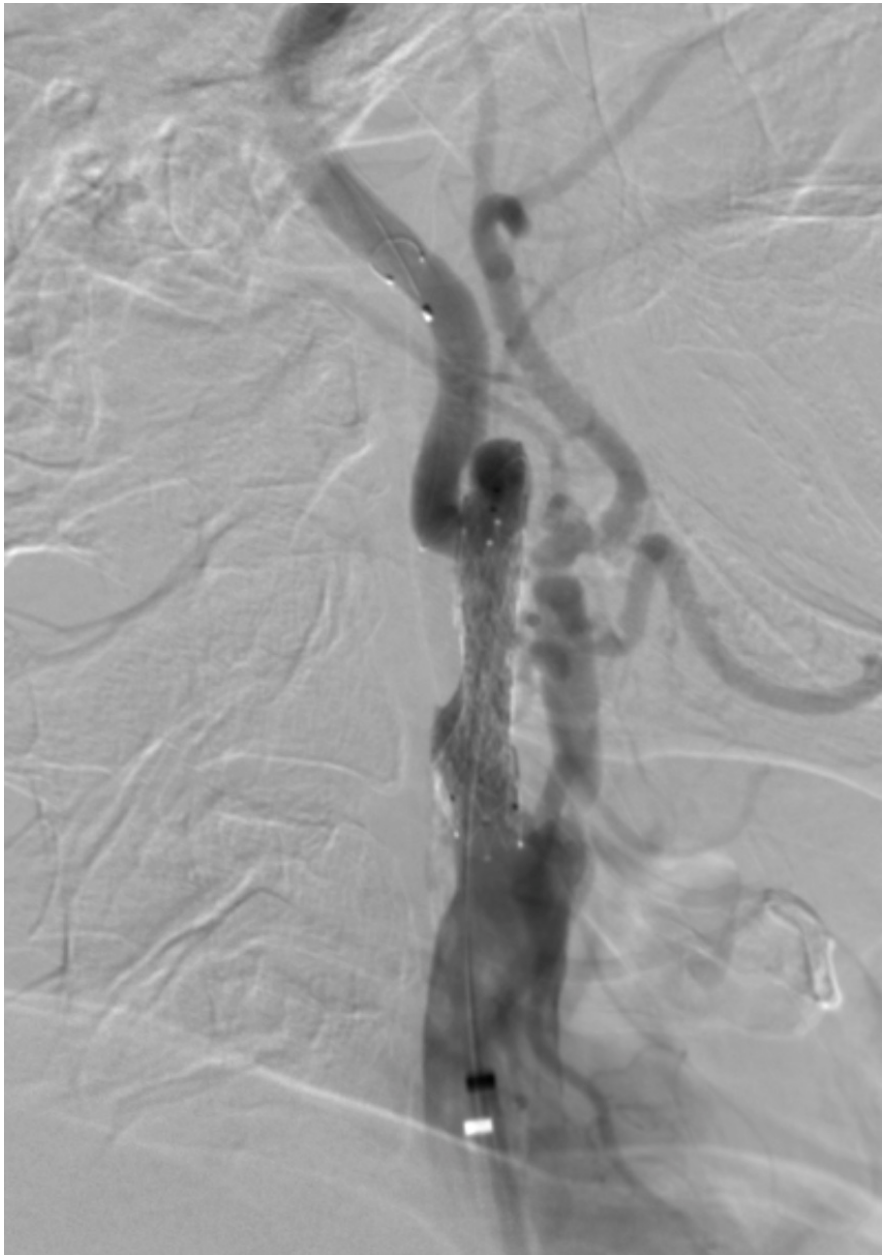

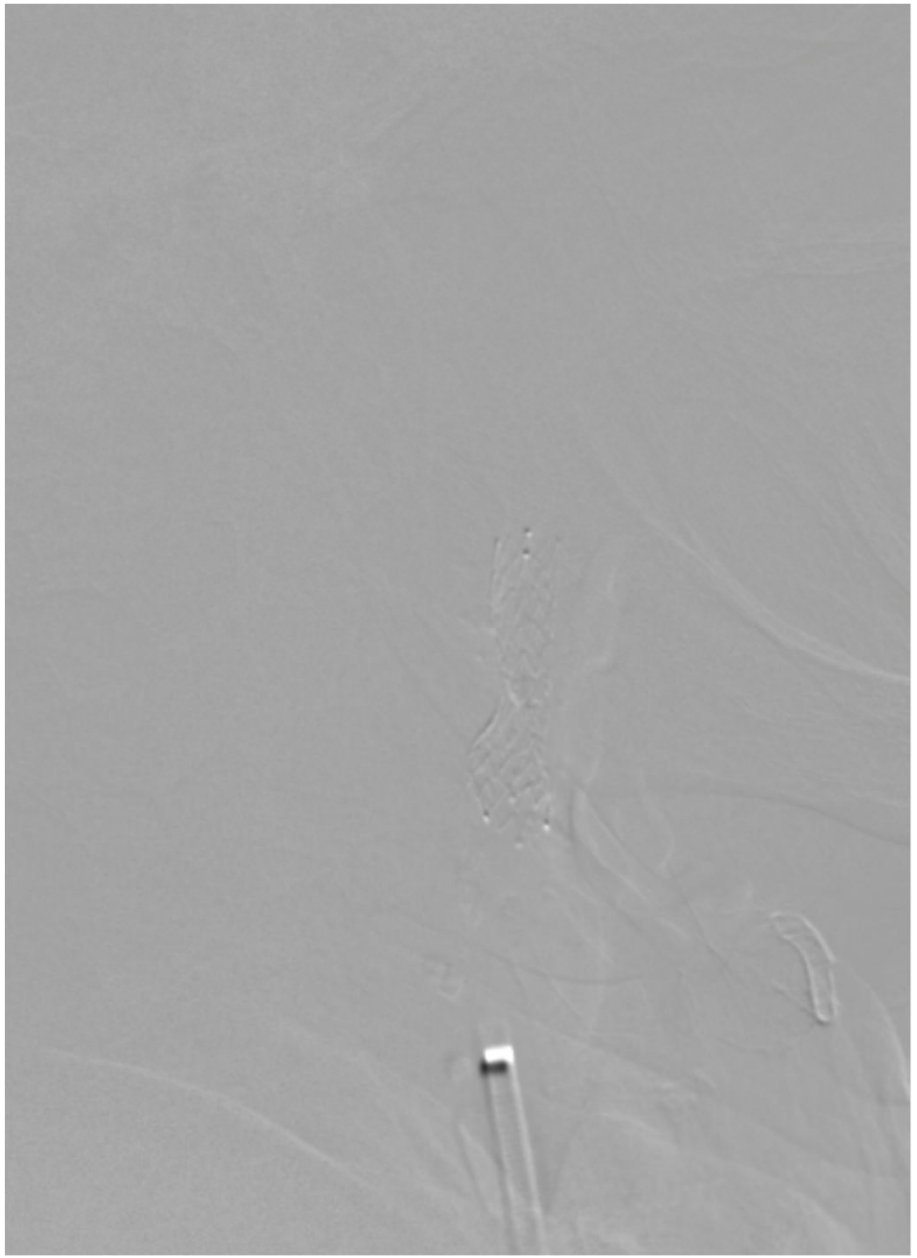

CAS EPS

- These patients suffered from no peri-postoperative neurological incidents.
- No other complications were noticed

Thank You. ☺

References

- „Imaging of high-risk carotid artery plaques: current status and future directions” J. Kevin DeMarco, M.D.,1 and John Huston III, M.D, Neurosurg Focus 36 (1):E1, 2014
- „Characteristics of carotid plaque findings on ultrasonography and black blood magnetic resonance imaging in comparison with pathological findings”, Arai D1, Yamaguchi S, Murakami M, Acta Neurochir Suppl. 2011;112:15-9
- „Association between Plaque Echogenicity and Embolic Material Captured in Filter during Protected Carotid Angioplasty and Stenting” T.G.Giannakopoulos, K.Moulakakis, European Journal of Vascular and Endovascular Surgery, Volume 43, Issue 6, June 2012, Pages 627-631
- „Stenting versus Endarterectomy for Treatment of Carotid-Artery Stenosis”, Thomas G. Brott, M.D., Robert W. Hobson, II, M.D., N Engl J Med 2010; 363:11-23, 1 july 2010
- CGuard EPS product characteristics